

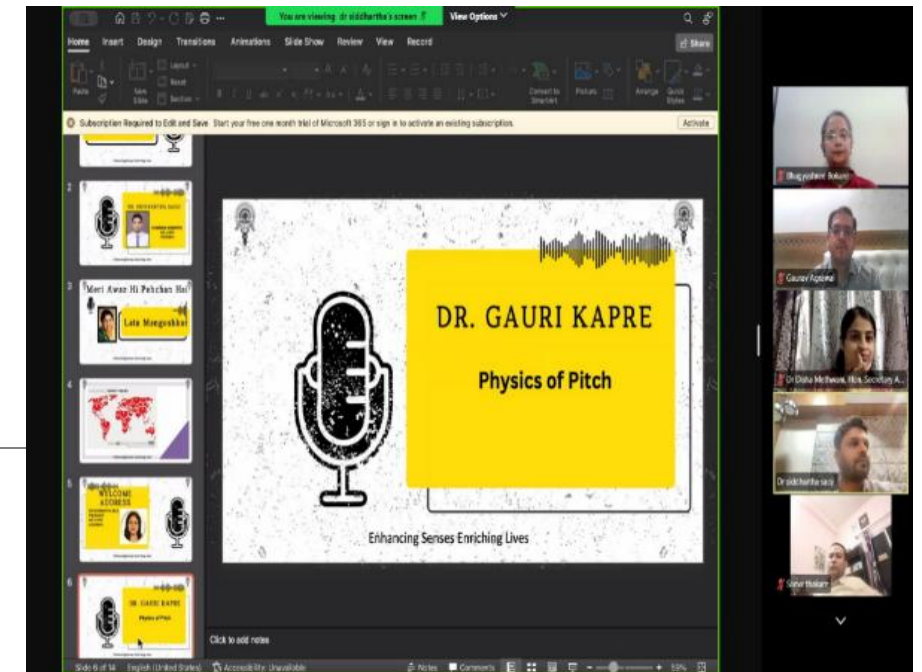
ACADEMIC STRIDES

April to June 2025

WEBINAR ON WORLD VOICE DAY

Organized by AOI Vidarbha

Dr Gauri Vaidya spoke on “The Physics of Pitch”



INTERESTING CASE PRESENTATION PROGRAM

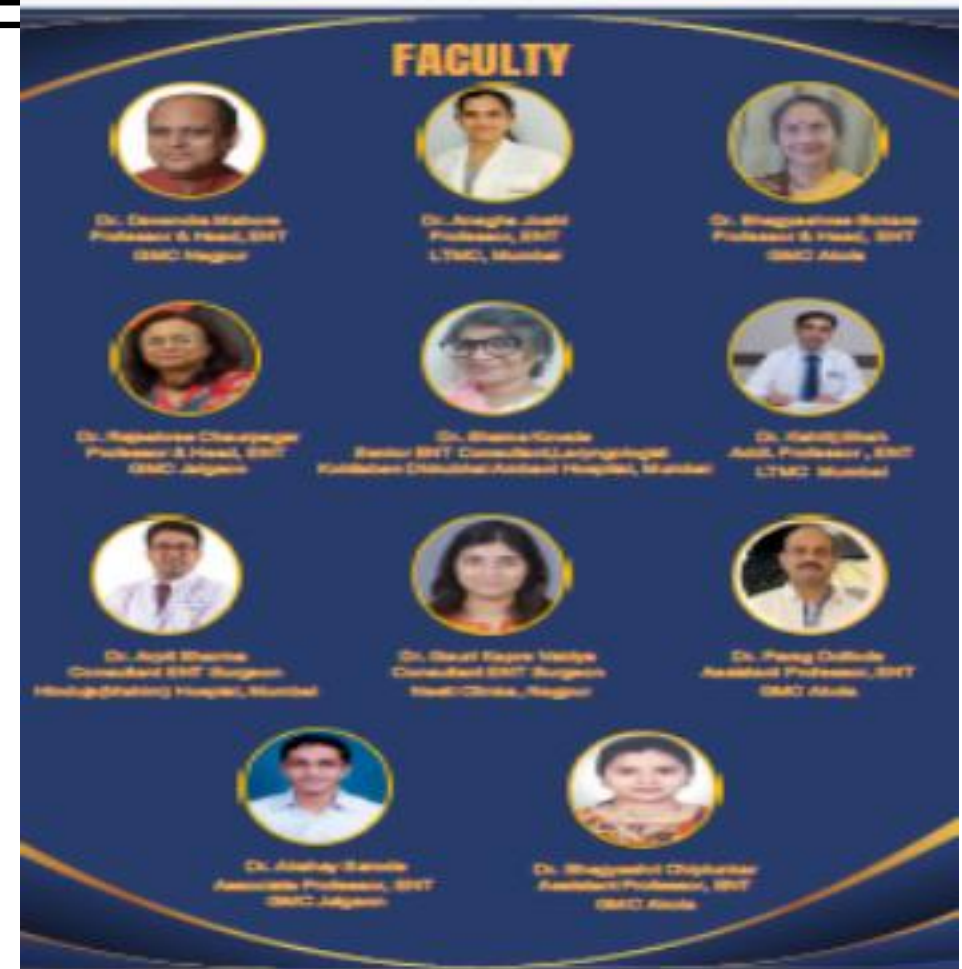Organized by ISA Nagpur

Dr Vidula Kapre presented case
“Management of patient with Tracheal
Rupture”



WEBINAR BY AOI AKOLA

Dr Gauri Vaidya spoke on “Principles of Phonomicrosurgery”



VERTIGO ISP

Dr Gauri Vaidya spoke on “Diagnosis of Vertigo”



THYROID CONCLAVE AT MAHAMANA REGIONAL CANCER CENTER VARANASI

Dr Madan Kapre gave

- Key Note address on “Avoiding complications in Thyroid Surgery”
- Talk on “Management of Recurrent Thyroid Cancers”
- Video demonstration of Thyroid Surgery



PANEL DISCUSSION ON THYROID SURGERY

Organized by AOI Vidarbha

Dr Madan Kapre and Dr Neeti Gupta as
Panelists

POSTER PRESENTATION COMPETITION

Organized by ISA
Nagpur
Dr Vidula Kapre as
judge



INSTRUCTIONAL COURSE ON STROBOSCOPY

Organized by AOI Vidarbha

Dr Gauri Vaidya as Faculty




ACADEMIA DIABETES CONFERENCE

Held at GMC Nagpur

Dr Madan Kapre as panelist in Panel Discussion on “Sleep Disorders”

SMART CME

Dr Madan Kapre spoke on
“Differential Diagnosis of LPR and
Role of RAFT Formulations”



WEBINAR ON ALLERGY

Organized by Neeti Clinics

Dr Raksha Dhabekar spoke on “Understanding Allergies”

Dr Gauri Vaidya as Moderator



NEETI CLINICS

Neeti Clinics Presents Exclusive Webinar

UNDERSTANDING ALLERGIES

👉 Causes 👉 Symptoms 👉 Solutions

Join us for an interactive session with

Dr. Raksha Dhabekar
(ENT Consultant at Neeti Clinics)
and learn how to manage allergies the right way!

DATE **21st** Saturday June 2025 TIME **2 PM to 3 PM**

📺 Via Zoom

Limited Spots Available!

To Register WhatsApp us on **9823866688** or Fill the form in our bio!

21, Neeti Gaurav Complex, Central Bazar Road, Ramdaspath, Nagpur, MH-440010

www.neeticlinics.com

COGNITIA

Conference for Undergraduates

Organized at GMC Nagpur

Dr Madan Kapre as Chief Guest

Interesting Cases

April to June 2025

Interesting Cases

ENDOSCOPIC REPAIR OF CSF LEAK:

- 1) A 54 - year female patient presented with leak of Cerebrospinal fluid from the nose. The defect was sealed endoscopically with tissue from the thigh and surgical glue.
- 2) A 58 - year lady had CSF leak from the nose due to defect in cribriform plate. There was also small meningocele from the defect. The meningocele was cauterized, fat and fascia lata were used to seal the defect. Repair was augmented with gel foam.

TOTAL THYROIDECTOMY OF A VERY LARGE GOITER: A 45-year female patient had a huge goiter for last 25 years. Refused surgery at various other centers. The large size of goiter was causing airway compression and deviation. Awake Fiberoptic Intubation was planned. Pulmonologist was called for the awake intubation but even for him the intubation was challenging. In spite of huge size of goiter there was no significant bleeding, no injury to Recurrent Laryngeal Nerve or damage to Parathyroid Glands.

Interesting Cases

MUCORMYCOSIS: After the post Covid phase of mucormycosis, our center gets periodic referrals for mucormycosis patients.

- 1) A 63-year male patient was operated for Sinonasal Mucormycosis.
- 2) A 54-year male patient had been operated for FESS at another center. He had received Inj Amphotericin for 12 days. Patient was hypertensive and had uncontrolled diabetes. He also had deranged renal function. Patient had chemosis, ptosis and proptosis of both eye lids. He also had IV and V cranial nerve palsy. Radical Endoscopic Debridement Surgery was done to clear the mucormycosis. Postoperatively patient had to be administered Inj Amphotericin with close monitoring of blood sugar and renal parameters.

THYROID SURGERIES: As our center is well recognized for thyroid surgeries, each month we operate on more than 10 thyroid surgeries which is way above the definition of a high-volume thyroid center.

FREE FIBULA MICROVASCULAR FLAP: was performed to reconstruct Mandibular defect after Mandibulectomy in a patient with Ca Lower Gingivo Buccal Sulcus.

Interesting Cases

ATRIAL FIBRILLATION: A 57-year patient was to undergo Mandibulectomy for Ca Gingivo Buccal Sulcus. He was found to have Atrial fibrillation. Thorough cardiovascular evaluation was done. Patient was optimised with tab Dilzem and Beta blockers. Throughout the surgery patient was asymptomatic. On first post operative day in the morning patient started having tachycardia. Throughout patient was comfortable, maintaining BP and saturation but rate remained high. Finally, patient settled with Amiadarone infusion.

SEVERE OSA WITH OBESITY: A 65-year male patient had to undergo excision of buccal mucosa lesion and reconstruction. Patient was obese, poorly controlled diabetic, hypertensive and had significant Obstructive Sleep Apnea. BP was maintained with low dose NTG infusion and short acting anaesthetic agents were used. This provided a good surgical field and patient was alert and able to maintain saturation postoperatively.

ORBITAL NERVE DECOMPRESSION: A 68 yr male patient presented with Optic Nerve Compression and Ptosis due to sinusitis. Patient had hypertension, uncontrolled diabetes and was very obese. At rest his SpO2 was 94% and his respiratory efforts were very shallow. Short acting anesthetic agents were used which would have a quick clearance. Tight control of blood sugar was maintained by regular monitoring and Inj Insulin. Patient made smooth postoperative recovery and at the first follow up visit he could even open his eye and had partially gained vision in the affected eye.

Interesting Cases

BALLOON DILATATION: A 42yr male patient was treated with balloon dilatation for tracheal stenosis. After the dilatation his airway lumen was near normal.

Teaching Activities

Dr. Kyvalya Turlapati Published original case report for Laryngeal Mucormycosis on the behalf of Neeti Clinics in the International Journal of Otolaryngology and Head and Neck Surgery.

A journal club was conducted on landmark articles on Oropharyngeal cancers and role of Chemotherapy in Head and Neck Cancers.